

CASE REPORT

# Primary haemangiopericytoma of the parapharyngeal space: an unusual tumour and review of the literature

## *Emangiopericitoma primario dello spazio parafaringeo: un tumore insolito e revisione della letteratura*

E.N. FOUNTOLAKIS, E. PAPAOKAKI<sup>1</sup>, I. PANAGIOTAKI, E. GIANNIKAKI<sup>2</sup>, G. LAGOUDIANAKIS, J. BIZAKIS

Department of Otorhinolaryngology; <sup>1</sup> Department of Radiology; <sup>2</sup> Department of Histopathology, University Hospital of Heraklion, Crete, Greece

### SUMMARY

Haemangiopericytoma is a rare soft tissue tumour, with great histological variability and unpredictable clinical and biological behaviour. The precise cell type origin is uncertain. One third of haemangiopericytomas occur in the head and neck area, but only a few cases have been reported regarding localization at the parapharyngeal space. Herewith, case is presented of a 54-year-old female, referred to our Department due to a parapharyngeal space tumour with non-specific imaging characteristics. The patient underwent radical excision of the tumour with a trans-cervical sub-mandibular approach. The histopathologic examination revealed a neoplasm with the characteristic features of haemangiopericytoma. One year later, during the scheduled follow-up, the computerized tomography scan showed no evidence of recurrence or residual disease. The pre-operative evaluation of a haemangiopericytoma must include a thorough imaging evaluation with computerized tomography and magnetic resonance imaging, even if results may not be specific for haemangiopericytoma. Angiography and pre-operative embolization may be performed in cases of large tumours with significant vascularity. The treatment of choice is radical excision. The follow-up includes clinical evaluation every 6 months and annual magnetic resonance imaging for at least 3 years.

KEY WORDS: Parapharyngeal space tumours • Haemangiopericytoma • Stilomandibular tenotomy

### RIASSUNTO

*L'emangiopericitoma è un raro tumore delle parti molli di origine cellulare incerta, con alta variabilità istologica ed un comportamento clinico e biologico imprevedibile. Solamente un terzo dei casi esordisce nella regione cervico-facciale, mentre solo pochi casi sono stati riportati per quanto riguarda la localizzazione nello spazio parafaringeo. Presentiamo il caso di una paziente di 54 anni che è stata riferita al nostro Dipartimento con un tumore vascolare dello spazio parafaringeo di dimensioni 3,5 × 2,8 × 3 cm. Le caratteristiche fornite dalla diagnostica per immagini del tumore non erano specifiche. La paziente è stata sottoposta alla completa e radicale escissione del tumore tramite un approccio transcervicale-sottomandibolare. L'esame istopatologico ha rivelato una neoplasia con le caratteristiche dell'emangiopericitoma. Un anno dopo l'intervento, il follow-up effettuato con tomografia computerizzata ha dimostrato l'assenza di malattia ricorrente o residua. La valutazione preoperatoria dell'emangiopericitoma deve includere una dettagliata valutazione con diagnostica per immagini (tomografia computerizzata e risonanza magnetica), anche se i risultati possono non essere specifici. L'angiografia e l'embolizzazione preoperatoria possono essere eseguiti in casi di grossi tumori altamente vascolari. Il trattamento di elezione è l'asportazione radicale. Il follow-up comprende una valutazione clinica ogni 6 mesi e l'esecuzione di una risonanza magnetica annuale almeno per 3 anni.*

PAROLE CHIAVE: Tumori dello spazio parafaringeo • Emangiopericitoma • Tendine stilomandibolare

Acta Otorhinolaryngol Ital 2011;31:194-198

### Introduction

Haemangiopericytoma (HPC) is a rare soft tissue tumour, which was first described, in 1942, by Stout and Murray<sup>1,2</sup> and was thought to originate from the pericyte, a specific cell type which surrounds the capillary vessels. However, the variable immunohistochemical profile of this tumour and its overlapping features with solitary fibrous tumours, created the belief that these two tumours are the two ends of one process, the origin of which is still unclear, ac-

ording to WHO endorsement. Despite the dispute, some investigators believe that HPCs arise from pluri-potential peri-vascular cells<sup>3</sup>. Approximately one-third of all HPCs occur in the head and neck<sup>4</sup> and, according to the literature, only a few cases of HPCs, in the parapharyngeal space, have been described<sup>5,6</sup>. HPCs are classified as benign, borderline, and malignant, depending on their histopathologic (mitotic activity, cellularity, and nuclear atypia) and clinical features (necrosis and tumour size)<sup>7,8</sup>. However, histo-pathological distinction between benign

and malignant HPCs may be difficult. Furthermore, the biological behaviour of these neoplasms is rather peculiar, as benign-looking, non-mitotic HPCs have been reported to metastasize. Given the high variability and the unpredictable pattern of the clinical and biological behaviour of HPCs, the treatment of choice is radical surgical excision.

### Case presentation

A 54-year-old female was referred to our Department from a Hospital of a neighbouring country with the diagnosis of a para-pharyngeal space tumour. The presence of the tumour had been detected 2 years previously in a CT scan, during the investigation of chronic headaches from which the patient suffered. It was located at the para-pharyngeal space and, according to the patient, the tumour had grown in size during the last 2 years. Six months before the patient's admission to our Department, an incisional biopsy was attempted, in a hospital, in her country, but the operation was not completed due to severe bleeding.

The clinical examination revealed a neck mass behind the angle of the left mandible, which caused significant displacement of the soft palate and the left tonsillar and peritonsillar region towards the midline. Upon palpation, the mass was fixed, soft, painless and non pulsatile. Except for a retracting scar, at the site of the attempted biopsy, the rest of the clinical examination was normal.

The MRI revealed an ovoid, well-defined tumour in the left parapharyngeal space  $3.5 \times 2.8 \times 3$  cm in size, which

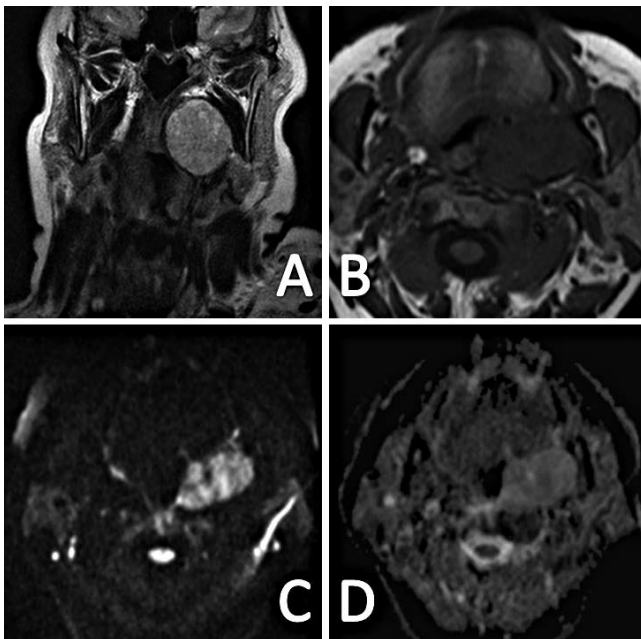
compressed and narrowed the oropharyngeal opening. The tumour showed low signal intensity, on T1 sequences, mild dyshomogeneous hyperintensity on T2 sequences, inhomogeneous low diffusivity, on diffusion weighted images (Fig. 1), as well as intense enhancement after intravenous Gadolinium administration (Fig. 2). The mass also compressed the adjacent pterygoid muscles, but no evidence of an anatomic relationship with the major vascular branches of the neck was detected.

The imaging characteristics of the tumour were non-specific. The differential diagnosis included highly vascularized parapharyngeal space masses, like mesenchymal tumours (angiosarcoma, leiomyosarcoma) or neurinogen tumours.

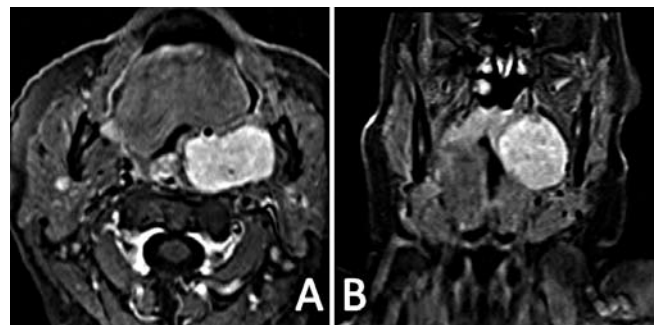
After a thorough pre-operative evaluation, the patient underwent complete excision of the tumour, via a transcervical-submandibular approach. A lateral neck incision was made just medially to the anterior margin of the sternocleidomastoid muscle, which was extended to the level of the left parotid gland. Then, an anterior dislocation of the mandible through stylo-mandibular tenotomy was performed, in order to provide sufficient exposure and ensure an adequate surgical field and the mass was removed to the level of the pharyngeal musculature. Particular concern was focused on the site of the attempted biopsy, as the post-traumatic fibrosis and adhesions made the excision particularly difficult. After haemostasis, a Penrose drainage was placed and suture closure was performed.

The post-operative recovery was uneventful and the Penrose drainage was removed on the 2<sup>nd</sup> post-operative day. The patient was finally dismissed on the 4<sup>th</sup> post-operative day.

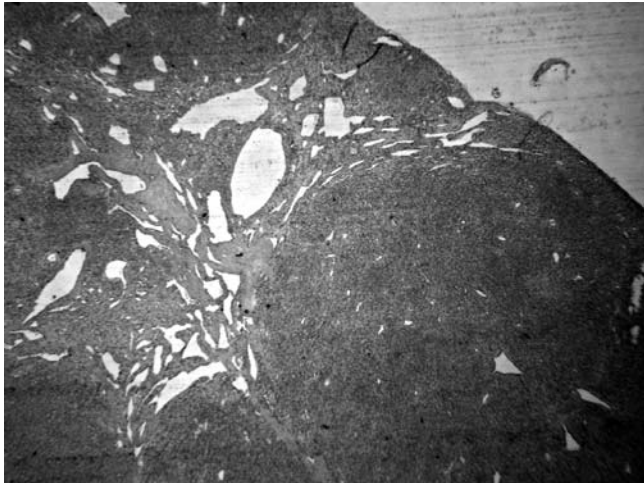
The histopathologic examination revealed a neoplasm with the histopathological and immunohistochemical features of HPC, consisting of spindle and ovoid cells with mild nuclear atypia and low mitotic rate (up to 1 mitosis/10 HPF). The neoplastic cells showed extensive reactivity for CD34 and bcl2 and they were negative for SMA, S100, chromogranin and synaptophysin (Figs. 3, 4). As the tumour was removed in pieces, due to the presence of



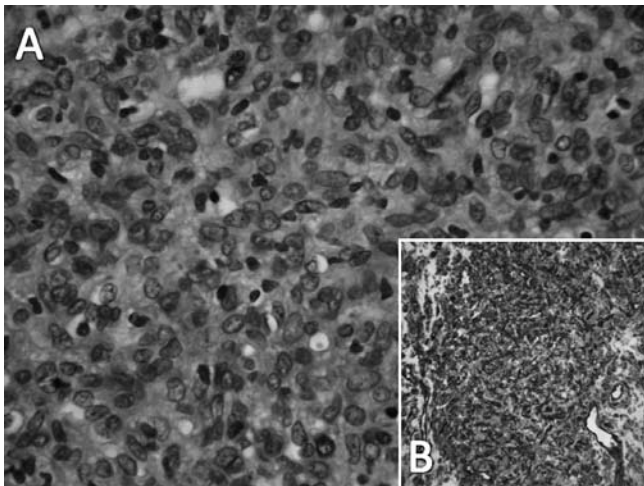
**Fig. 1.** MRI revealed an ovoid, well-defined mass in the left parapharyngeal space with mild inhomogeneous hyperintensity on T2 sequences (A), low signal intensity on T1 sequences (B) and inhomogeneous low diffusivity on diffusion weighted images (C) and ADC map (D).



**Fig. 2.** The tumour compressed and narrowed the oropharyngeal opening, characterized by intense enhancement after intravenous Gadolinium administration (A, B), implying high vascularization.



**Fig. 3.** Microscopic view of haemangiopericytoma showing a circumscribed lesion, with the characteristic vascular pattern and a partial "staghorn" configuration and spindle cell areas. (H&E, X 20)



**Fig. 4.** [A] High power view of the spindle cell areas. The spindle cells show no atypia, mitosis or necrosis. (H&E, X 400). [B] The spindle cells express cytoplasmic positivity in CD34 (immunohistochemistry, X 400).

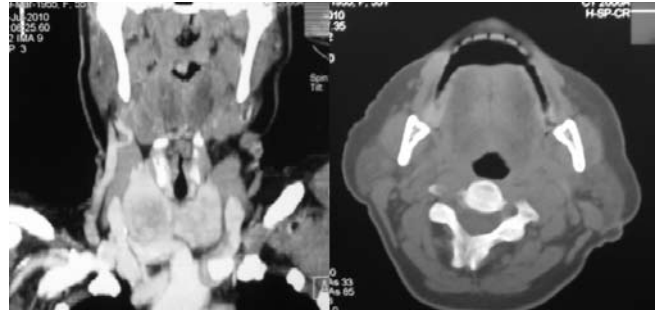
adhesions and particular friability of the mass, evaluation of the surgical margins was not possible.

One year later, during scheduled follow-up, the CT scan showed no evidence of recurrence or residual disease (Fig. 5).

## Discussion

A wide variety of benign and malignant tumours can occur in the parapharyngeal space. The management of a patient with such a tumour, represents a challenge for the Head and Neck Surgeon.

HPC is a neoplasm of uncertain cell type origin. It is an uncommon spindle cell tumour, constituting 2.5% of soft tissue neoplasms and occurs primarily in adult life (median age 45 yrs, with peak prevalence in the sixth to seventh decade of life), appearing with an equal sex dis-



**Fig. 5.** CT scan performed one year after the operation. No evidence of recurrence.

tribution<sup>9-11</sup>. It is frequently aggressive and has a tendency to recur and metastasize. Approximately one-third of all HPCs occur in the head and neck. Primary parapharyngeal space HPCs are very rare neoplasms and, according to the international literature, only a few cases have been reported, with some of them referring to tumours that invade the parapharyngeal space from other sites of the head and the neck<sup>12</sup>.

A painless mass is the most common presentation of head and neck HPCs. The clinical behaviour varies depending on the different grading of each case. The diagnosis cannot be made on the basis of clinical and gross morphologic characteristics. Definitive diagnosis of HPC is provided by the accurate histopathologic assessment, which determines the accurate management and prognosis<sup>13</sup>. The prediction of the clinical behaviour of HPC is not always clear and does not always correlate with the histopathologic features of the tumour. Strict universal histopathologic criteria, for malignancy, have not been identified and vary between different studies. Generally, large size (> 5 cm), increased mitotic rate (> 4 mitosis/10 HPF), with the presence of atypical mitosis, high cellularity, pleomorphic tumour cells and foci of haemorrhage and necrosis predict a highly malignant course<sup>8,13</sup>.

The correct pre-operative imaging evaluation of HPCs is of great importance for scheduling the surgical plan. The tumour usually appears as a solid mass, hypodense on CT and isointense on T1-weighted images on MRI. On T2-weighted images, the tumour shows equal or lower signal intensity compared with the surrounding structures, although, in some cases, hyperintense signals have been described<sup>14</sup>. Due to better contrast resolution, MRI is superior compared to CT in demonstrating the morphological characteristics of these tumours, as well as their extension to the contiguous anatomical structures, especially at the base of the skull. In these highly vascularized tumours, vessels could also be seen as signal voids, on MRI, but not on CT. Although MRI is essential for accurate surgical planning and should be referred as the "gold standard", the imaging characteristics of the HPCs may be non-specific, demanding a differential diagnosis from other types of vascular or non-vascular tumours, especially those with

prominent vascularization, such as juvenile haemangioma, glomus tumour, angiosarcoma, leiomyoma, leiomyosarcoma, schwannoma, mesothelioma, liposarcoma, benign and malignant histiocytoma, synovial sarcoma, chondrosarcoma, neuroblastoma, adenoid cystic carcinoma and mixed cell tumour<sup>15 16</sup>.

Conventional angiography may be helpful for pre-operative differential diagnosis and is useful for the possibility of pre-operative embolization<sup>5 17</sup>, which has been suggested as an option for decreasing tumour vascularity and size. Moreover, some Authors use routine angiography and peri-operative embolization in order to reduce intra-operative haemorrhage<sup>18</sup>. In our patient, there was no need for such a procedure due to the small size of the tumour.

Although histopathology of HPCs has been well documented, fine-needle aspiration biopsy (FNAB) findings have rarely been described in the literature<sup>19-21</sup>. A primary diagnosis of HPC is difficult to make with the use of FNAB. Cytologic analysis may allow the diagnosis of a recurrent or metastatic HPC<sup>20</sup>.

In our Department, we do not advise incisional biopsy for tumours with considerable vascularity, due to the fear of bleeding and consequent fibrosis. Furthermore, we do not use FNAB because, these tumours will eventually be treated surgically, regardless of the pre-operative cytologic findings. FNAB may be particularly helpful in cases in which the suspicion of harbouring a malignancy is high. The treatment of choice is radical excision of the HPC with a sufficient cuff of healthy tissue. Unfortunately, this is not always possible for para-pharyngeal space tumours, making the need of adequate exposure mandatory, which is accomplished by stylo-mandibular tenotomy.

Adjuvant radiotherapy and chemotherapy may be employed, although the literature is not quite clear about their results. HPCs are considered to be relatively resistant to radiotherapy. Radiotherapy is reserved only as adjuvant therapy in cases of incompletely excised lesions, recurrent tumours, and tumours with high-grade histopathologic features. Although chemotherapy may have a role in the treatment of distant metastatic disease, its role in the primary treatment remains to be clearly defined. Vincris-

tine, Adriamycin, and Cyclophosphamide have all been used with variable success in cases of aggressive HPCs (8Y10). Some additional reports show that the use of interferon may be of benefit in patients with pulmonary HPC metastases<sup>22</sup>.

HPC appears to present a survival rate that may vary from an overall 10-year rate of 70%<sup>8</sup> to a considerably reduced 10-year survival rate in cases of > 4 mitosis/10 HPF (9%) or necrosis (29%) or tumour size > 6.5 cm (63%)<sup>9</sup>. Some studies report local recurrence rates as high as 40%, with metastatic disease in 15% of the cases<sup>23</sup> reported to have a latency period which varies from 63 to 107 months<sup>24</sup>.

No clear consensus, regarding the follow-up planning, seems to exist. In our case, we propose clinical evaluation every 6 months and an annual imaging study for at least 3 years. In our case, the patient performed a CT scan 1 year after the operation with no evidence of recurrence or residual disease

## Conclusions

Haemangiopericytoma is a rare soft tissue tumour of uncertain cell type origin, with high histological variability and unpredictable clinical and biological behaviour. One third of HPCs occur in the head and the neck and only a few cases have been reported regarding localization in the parapharyngeal space.

Pre-operative evaluation must include a thorough imaging evaluation (CT and MRI scan), even if the results may not be specific for haemangiopericytoma. Angiography and pre-operative embolization may be performed in large tumours with significant vascularity, in order to decrease the size and vascularity of the tumour.

The treatment of choice is radical excision, and the follow-up we propose includes clinical evaluation every 6 months and an annual MRI for at least 3 years. Incisional biopsy and pre-operative FNAB is not routinely used in our Department, due to the high incidence of bleeding and fibrosis and because, regardless of the histo-pathological pattern, total excision will eventually be performed. FNAB is advised when high suspicion of malignancy exists.

## References

- 1 Stout AP, Murray MR. *Hemangiopericytoma: a vascular tumor featuring Zimmermann's pericytes*. Ann Surg 1942;116:26-33.
- 2 Carvalho JR, Haddad L, Leonhardt FD, et al. *Head and neck hemangiopericytoma in a child: case report*. Sao Paulo Med J 2004;122:223-6.
- 3 Ide F, Obara K, Mishima K, et al. *Ultrastructural spectrum of solitary fibrous tumor: A unique perivascular tumor with alternative lines of differentiation*. Virchows Arch 2005;446:646-52.
- 4 Russell WO, Cohen J, Enzinger F, et al. *A clinical and pathological staging system for soft tissue sarcomas*. Cancer 1977;40:1562-70.
- 5 Llorente JL, Suárez C, Ablanedo P, et al. *Hemangiopericytoma of the parapharyngeal space*. Otol Head Neck Surg 1999;120:531-3.
- 6 Wakisaka N, Kondo S, Muroso S, et al. *A solitary fibrous tumor arising in the parapharyngeal space, with MRI and FDG-PET findings*. Auris Nasus Larynx 2009;36:367-71.
- 7 McMaster MJ, Soule EH, Ivins JC. *Hemangiopericytoma. A clinicopathologic study and long-term follow-up of 60 patients*. Cancer 1975;36:2232-44.

- <sup>8</sup> Enzinger FM, Smith BH. *Hemangiopericytoma. An analysis of 106 cases.* Hum Pathol 1976;7:61-82.
- <sup>9</sup> Billings KR, Fu YS, Calcaterra TC, Sercarz JA. *Hemangiopericytoma of the head and neck.* Am J Otolaryngol 2000;21:238-43.
- <sup>10</sup> Ghaffar H, Parwani A, Rosenthal DL. *Fine-needle aspiration cytology of hepatic metastasis from a meningeal hemangiopericytoma – A case report.* Acta Cytol 2003;47:281-6.
- <sup>11</sup> Chhieng D, Cohen J, Fernandez G, et al. *Fine-needle aspiration cytology of hemangiopericytoma: a report of five cases.* Cancer 1999;87:190-5.
- <sup>12</sup> Katsantonis GP, Friedman WH, Rosenblum BN. *The surgical management of advanced malignancies of the parotid gland.* Otol Head Neck Surg 1989;101:633-40.
- <sup>13</sup> Middleton LP, Duray PH, Merino MJ. *The histological spectrum of hemangiopericytoma: application of immunohistochemical analysis including proliferative markers to facilitate diagnosis and predict prognosis.* Hum Pathol 1998;29:636-40.
- <sup>14</sup> Acioglu E, Cansiz H, Mercan H, et al. *Head and neck hemangiopericytomas: diagnostic contradictions.* J Craniofac Surg 2009;20:930-5.
- <sup>15</sup> Catalano PJ, Brandwein M, Shah DK, et al. *Sinonasal hemangiopericytomas: a clinicopathologic and immunohistochemical study of seven cases.* Head Neck 1996;18:42-53.
- <sup>16</sup> Hervé S, Abd Alsamad I, Beautru R, et al. *Management of sinonasal hemangiopericytomas.* Rhinology 1999;37:153-8.
- <sup>17</sup> Carrau RL, Johnson JT, Myers EN. *Management of tumors of the parapharyngeal space.* Oncology 1997;11:633-40.
- <sup>18</sup> Craven JP, Quigley TM, Bolen JW, et al. *Current management and clinical outcome of hemangiopericytomas.* Am J Surg 1992;163:490-3.
- <sup>19</sup> Sawh RN, Lele SM, Borowski J, et al. *Fine-needle aspiration cytology of hemangiopericytoma: report of two cases.* Diagn Cytopathol 2000;23:187-91.
- <sup>20</sup> Geisinger KR, Silverman JF, Cappellari JO, et al. *Fine-needle aspiration cytology of hemangiopericytoma with ultrastructural and flow cytometric analyses.* Arch Pathol Lab Med 1990;114:705-10.
- <sup>21</sup> Shimizu K, Ogura S, Kobayashi TK, et al. *Fine-needle aspiration cytology of malignant hemangiopericytoma of the salivary gland: A case report.* Diagn Cytopathol 1999;21:398-401.
- <sup>22</sup> Lackner H, Urban C, Dornbusch HJ. *Interferon alfa-2a in recurrent metastatic hemangiopericytoma.* Med Pediatr Oncol 2003;40:192-4.
- <sup>23</sup> Carrew JF, Sing B, Kraus DH. *Hemangiopericytoma of the head and neck.* Laryngoscope 1999;109:1409-11.
- <sup>24</sup> Guthrie BL, Ebersold MJ, Scheithaurer BW, et al. *Meningeal HPC histopathological features, treatment and long term follow-up of 44 cases.* Neurosurgery 1989;25:514-22.

Received: April 28, 2010 - Accepted: August 25, 2010 – EPUB March 16, 2011